

Rapid prototyping-assisted fabrication of the customized metatarsophalangeal joint implant (SamKu)

A case report

Sameer C. Raghatare

Raghatare City Nursing Home, Nagpur, India

Abhaykumar M. Kuthe

Department of Mechanical Engineering, Visvesaraya National Institute of Technology, Nagpur, India

Tushar R. Deshmukh

Department of Mechanical Engineering, Prof Ram Meghe Institute of Technology & Research, Amravati, India, and

Sandeep W. Dahake

Department of Mechanical Engineering, Visvesaraya National Institute of Technology, Nagpur, India

Abstract

Purpose – The main purpose of this paper is to report the successful treatment modality for patients suffering from arthritis of the metatarsophalangeal joint (MTPJ) of the foot which otherwise could not be treated through traditional surgeries.

Design/methodology/approach – The unique capabilities of the computer-aided design and the rapid prototyping (RP) technology are used to develop the customized MTPJ implant (SamKu).

Findings – This approach shows good results in the fabrication of the MTPJ implant. Postoperatively, the patient experienced normalcy in the movement of the MTPJ of the foot.

Practical implications – Advanced technologies made it possible to fabricate the customized MTPJ implant (SamKu). The advantage of this approach is that the physical RP model assisted in designing the final metallic implant. It also helped in the surgical planning and the rehearsals.

Originality/value – This case report illustrates the benefits of imaging/computer-aided manufacturing/RP to develop the customized implant and serve those patients who could not be treated in the traditional way. This is a pioneered attempt toward implementation of a customized implant for patients suffering from arthritis of the MTPJ.

Keywords Rapid prototyping, Custom implant, Computer-aided modeling, Medical treatment, SamKu

Paper type Research paper

1. Introduction

Arthritis of the metatarsophalangeal joint (MTPJ) is a rare injury. This paper describes the management of a case of destruction of the second, third and fourth MTPJs. This case illustrates the difficulty of management and treatment of arthritis of MTPJ in the presence of multiple foot injuries. Only a few cases of MTPJ fracture dislocations have been reported in the literature (Pai *et al.*, 2008; Hofstaetter *et al.*, 2005; Hatch *et al.*, 2003). Owing to the differences in the structure and the shape of the human anatomy, it is difficult to replace the MTPJ successfully without a highly customized implant. SamKu is a customized MTPJ implant which is made

as per patient's requirement. The name given to the implant is SamKu.

The underlying causes of disease or disorder of the MTPJ include osteoarthritis, rheumatoid arthritis, disease of the hallux sesamoids and post-traumatic degeneration. Disease or disorder of the MTPJ generates pain and induces reduction in the range of motion which affects shoe wear, ambulation and other activities of daily living (Grondal *et al.*, 2006). Conservative treatments include exercise, physiotherapy, supportive shoes worn alone or with soft/semi-rigid orthoses, non-steroidal anti-inflammatory drugs and steroid injections. Arthrodesis and resection are the two major surgical options for the MTPJs in reconstruction of a rheumatoid forefoot (Grondal *et al.*, 2006; Trieb *et al.*, 2005). Keller's orthoplasty may be the better choice in older patients (O'Doherty *et al.*, 1990).

If patients do not experience relief after conservative therapies, then many surgical procedures have been described for the

The current issue and full text archive of this journal is available at www.emeraldinsight.com/1355-2546.htm



Rapid Prototyping Journal
20/4 (2014) 270–279
© Emerald Group Publishing Limited [ISSN 1355-2546]
[DOI 10.1108/RPJ-08-2012-0077]

Received 23 May 2012
Revised 31 August 2012
Accepted 16 October 2012

treatment of MTPJ based upon the diagnosis, patient age and activity level. The simplest surgical procedure consists of shaving off the bony prominence interfering with joint movement (i.e. cheilectomy). When conservative medical management and less invasive procedures have failed, procedures involving joint destruction may be considered. Joint-destructive procedures include resection arthroplasty (i.e. removal of the medial eminence on the metatarsal head and removal of part of the proximal phalanx, leaving a flexible joint; e.g. Keller's arthroplasty), arthrodesis (i.e. excision of the metatarsal head along with part of the proximal phalanx and fusion of the joint) and implant arthroplasty (i.e. partial or total joint replacement with an artificial implant). For a young, active patient, an arthrodesis is the gold standard, and the primary predictors of clinical and radiographical success are proper fusion angle alignment and maintenance or restoration of length. In an elderly or inactive patient, arthrodesis is a safe and reliable treatment option.

The rapid prototyping (RP) not only allows development of customized implants but also helps in pre-surgical planning. Traditional pre-surgical planning is based on the manipulation of the two-dimensional (2D) data obtained by the means of radiography and photography. This approach limits the full appreciation of various bony structure movements (Hibi *et al.*, 1997). RP is the technique used to produce the physical models based on the radiography image. Thus surgeons can visualize internal and external anatomy prior to the surgery. The anatomical areas in which the RP technology has been successfully applied at the international level are:

- maxilla-facial reconstruction;
- knee surgery;
- pelvic fracture;
- hip dysplasia, aseptic necrosis and epiphysiolysis;
- pinal trauma;
- congenital and degenerative spinal disease;
- skull plasticities; and
- craniostyosis and orthodontic surgery (Truscott *et al.*, 2004; Gopakumar, 2004; Petzold *et al.*, 1999; Joshi *et al.*, 2006; Sekou *et al.*, 2009; Chua *et al.*, 2000).

Medical models were built predominantly using the stereolithography (STL) and the fused deposition modeling (FDM) techniques of RP over the last few years (Deshmukh *et al.*, 2011; Winder and Bibb, 2005). Implementing the integrated approach of the medical imaging, computer-aided design (CAD), RP and computer-aided manufacturing (CAM) for fabricating the customized medical implants reduces lead time (Deshmukh *et al.*, 2011; Hieu *et al.*, 2003). The use of the custom-made or the pre-designed partial and/or the total artificial MTPJ implant remains one of the surgical alternatives for treating various MTPJ disorders when other conservative treatments fail (Pai *et al.*, 2008).

The case report presents a unique illustration of total MTPJ replacement with customized and the modified MTPJ prosthesis, which provides the best fit for the patient.

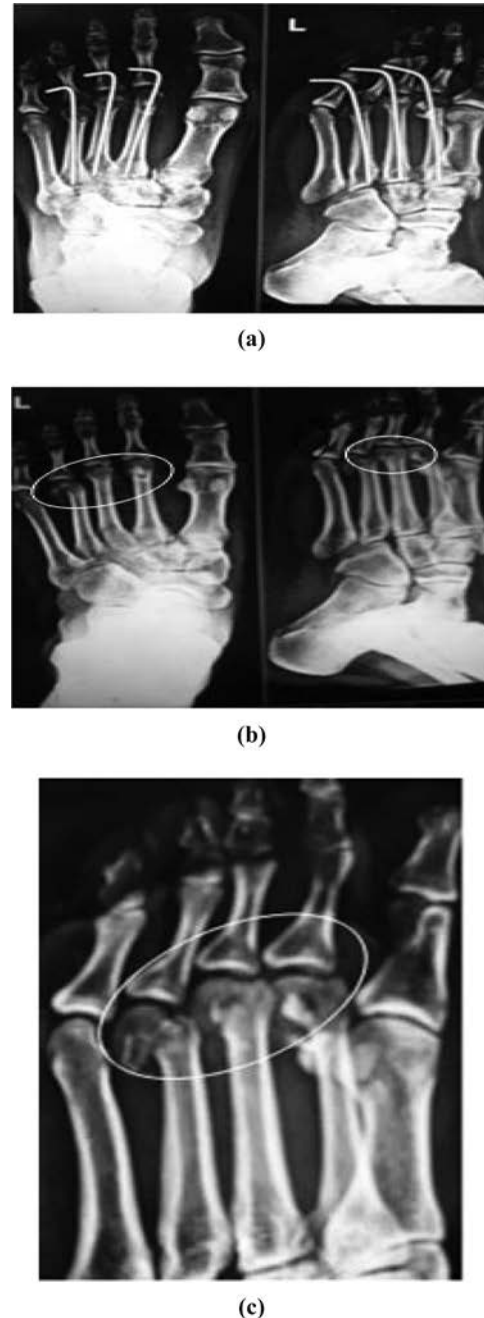
2. Materials and methods

2.1 Case report: background

Traumatic metatarsal fractures of the central three metatarsals usually occur as the result of a fall (www.myfootshop.com/

images/medical/x-rays/met_fx2_mod.jpg). Falls are often forward with the foot fixed and anchored on the ground by an object such as a pallet or hole in the ground. In this case, the foot is unable to roll forward with the body, resulting in a fracture of the metatarsal(s). The opposite can also hold true

Figure 1



Notes: (a) Radiograph of the anterior–posterior view of the diseased left foot with k-wires; (b) radiograph of the anterior–posterior view of the diseased left foot after removal of k-wires after 6 weeks; (c) radiograph shows arthritis in the second, third and fourth MTPJs after 10 weeks

where the foot is fixed, but the body falls back, resulting in fracture of one or more of the metatarsals.

Crush fractures of the forefoot often include traumatic fractures of the metatarsals (www.myfootshop.com/images/medical/x-rays/multiplemetfx.JPG). Crush fractures have no exact pattern of injury to result in traumatic fractures. Examples of crush fractures include auto accidents or dropping heavy loads on the forefoot. As load is applied to the MTPJ, strain in the joint occurs. Strain is a normal deformation process that takes place within every bone. However, in most cases, strain of the MTPJ can be repaired with a period of rest. If for any reason the strain cannot be repaired, stress occurs. Stress is the actual physical deformation of the bone joint and therefore fracture occurs.

In this case, a 30-year-old man met with an accident and broken the second, third and fourth MTPJs of the left foot. The patient was examined by an orthopedic surgeon, who fitted three k-wires, with closed reduction and percutaneous fixation, for supporting the broken MTPJ [Figure 1(a)]. The k-wires increase the incidence of painful stiffness of MTPJs, so their use has no advantage (Watson *et al.*, 1974). However, because of improper

Table I Approach of customized implant design

Radiograph
2D sketching
Conversion of 2D sketch into 3D image file
Conversion into .STL format
Data imported into catalyst software of RP machine
Slicing of 3D model
Feeding into RP machine

Table II Approach of customized implant manufacturing

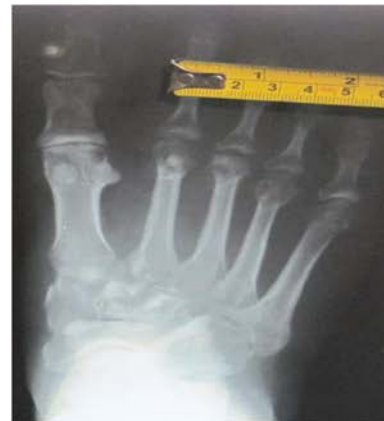RP machine
Layer by layer manufacturing of RP model
Mould preparation using RP part
Baking of mould
Investment casting (using SS316L material)
Post-processing using sandblasting
Burr smoothing
Rubber wheel cone polish
Finished implant

Table III Dimensions of second and third metatarsals and phalanges taken from radiograph

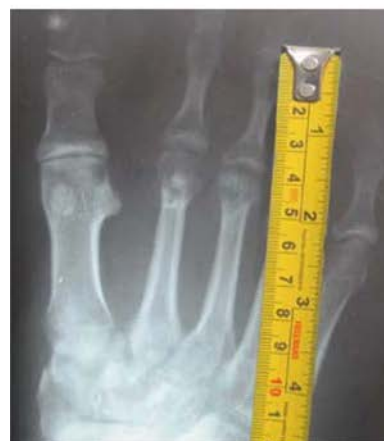Particulars	Bone size (mm)	
	Second	Third
<i>Metatarsal</i>		
Head (radius)	9	8
Neck (radius)	2	2
Isthmus (radius)	1.5	1.5
Length	70	67
<i>Proximal phalange</i>		
Base (radius)	4	3
Neck (radius)	2.5	2
Isthmus (radius)	1.5	1
Length	38	37

fixation of the joint and the resulting wear and tear, the joint surfaces were damaged. Pain and reduction in the range of motion, especially dorsiflexion, at the MTPJ resulted, thus affecting shoe wear, ambulation and other activities of daily living.

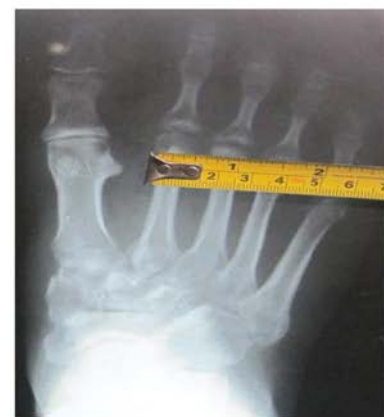Figure 2



(a)



(b)



(c)

Notes: (a); (b); (c) Radiograph showing bone dimensions

All three k-wires were removed after about 6 weeks. The radiograph suggested a diseased part of the MTPJ. The radiograph also confirmed the dislocation of the second and third MTPJ and showed the actual fracture position between the joints [Figure 1(b and c)]. The fourth MTPJ was normal.

2.2 Designing and customization of MTPJ implant

2.2.1 Data collection

A radiograph was acquired using an X-ray machine. The radiograph image was used for creating the RP model for the surgical planning and demo model. The 2D data were processed by the segmentation, and the soft tissues and the bone structures were separated to get the actual dimensions of the bone. The dimensions, size and shape were determined by the surgeons based on the radiograph. The next step was the image processing and a 3-D reconstruction to form a volumetric physical model. The 3-D CAD model was developed with the help of CAD software (Pro/Engineer wildfire 4.0; PTC), and then the RP model was fabricated. The tailor-made implant was then manufactured using RP-assisted casting. The detailed approach of the customized implant design and manufacturing is shown in Tables I and II.

2.2.2 Development of customized implant

The radiograph of the MTPJ was studied meticulously and used in the development of the implant. The dimensions of the implant are decided based on the bone size as noted in Table III from the radiograph [Figure 2(a-c)].

For example, it is observed in Table III that the head radius of the second metatarsal is 9 mm; to accommodate implant in the second metatarsal, the head radius for the implant is fixed as 3.9 mm.

The following important points are taken into consideration while designing the implant:

- range of motion of the joint;
- stability of implant with bone;
- strength and stress points/area (three stress points: contact point, mid prosthesis and end point);
- friction (internal surface polished and smooth); and
- cost and time.

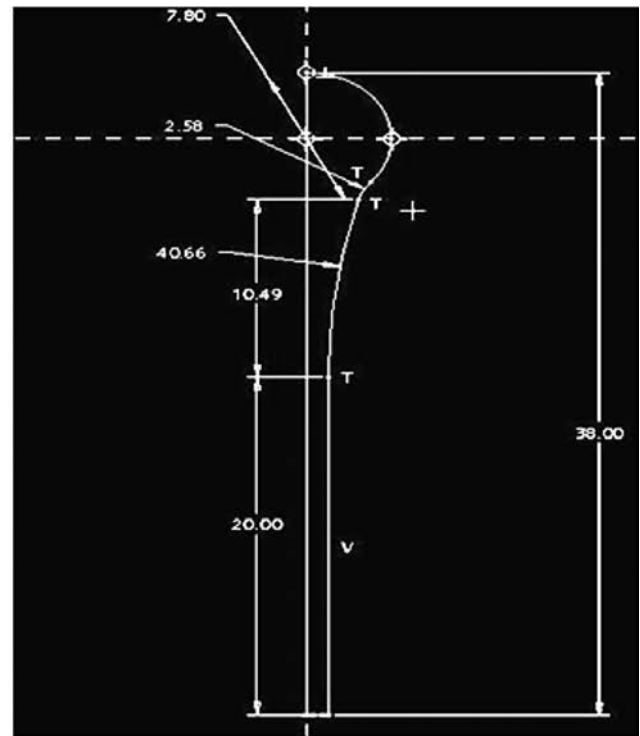
Thus, the complete dimensions of the implant are shown in Table IV.

In this case study, a cemented prosthetic implant is not preferred, as chances of failure of a cemented implant are

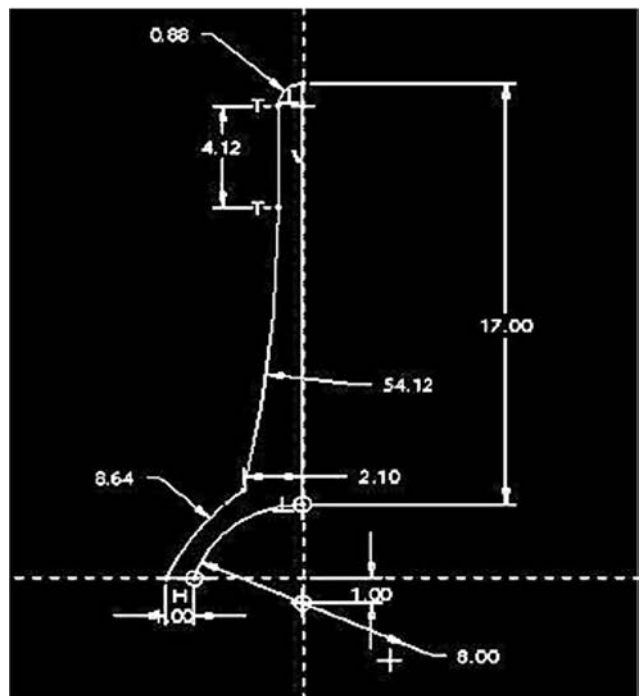
Table IV Implant dimensions based on the bone size

Particulars	Implant size (mm)	
	Second	Third
Metatarsal		
Head (radius)	3.9	3.9
Neck (radius)	2	2
Isthmus (radius)	1	1
Length	38	38
Proximal phalanges		
Base (cup inner radius)	4	4
Neck (radius)	2.10	2.10
Isthmus (radius)	0.88	0.88
Length	20	20

Figure 3 A 2D drawing of the MTPJ implant (SamKu)



(a)



(b)

Notes: (a) Metatarsal implant; (b) phalangeal implant

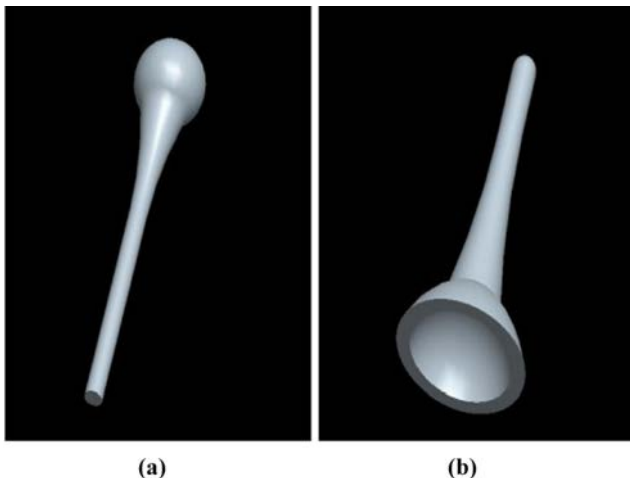
reported in the literature. Play of a few millimeters has been kept so that the prosthetic implant can adjust to the different complex movements of the foot, i.e. plantar and dorsiflexion, inversion and eversion and translation (Figure 3).

A compact and customized implant, along with the proper fixing arrangement, was needed. The part file in the form of an STL file is then imported in the catalyst (Figure 4) pre-processing software supplied along with the RP machine (Dimension BST machine, Stratasys Inc., Ontario, CA, USA) to get the acrylonitrile butadiene styrene (ABS) model of the MTPJ using the FDM method of the RP. The FDM process was chosen because of its minimum post-processing requirements and the superior mechanical properties, like strength of the build material (Ng et al., 2002). It has also proved that the satisfactory accuracy, the surface quality and the economy can be achieved using the FDM process (Xu et al., 1999; Bharath et al., 2000).

A custom-made MTPJ (SamKu) prosthesis conforming to the patient's specific anatomical morphology was then fabricated. To create a metallic model, investment casting is carried out using the RP model as a pattern (Figure 5). The material selected for the casting of the MTPJ implant (SamKu) was medical-grade cobalt chrome, a biocompatible material (Balazic et al., 2007). This alloy had been selected for its optimum combination of properties, including good casting, superior corrosion resistance, high elastic modulus and ultimate strength to withstand body forces and cost effectiveness in comparison with other biocompatible metals (Yan et al., 2007; Deshmukh et al., 2011). Sandblasting, burr smoothing and rubber wheel cone polish process were carried out to get the finished implant (Figure 6). All aspects like the age of patient, growth of bone size, working of the foot and the load on the MTPJ implant (SamKu) were considered while designing the implant. The age and the growth of the bone are directly proportional to each other. The purpose of the implant (SamKu) design was to restore normal functioning of the foot and to tolerate the body load while standing and walking and also for all daily living activities.

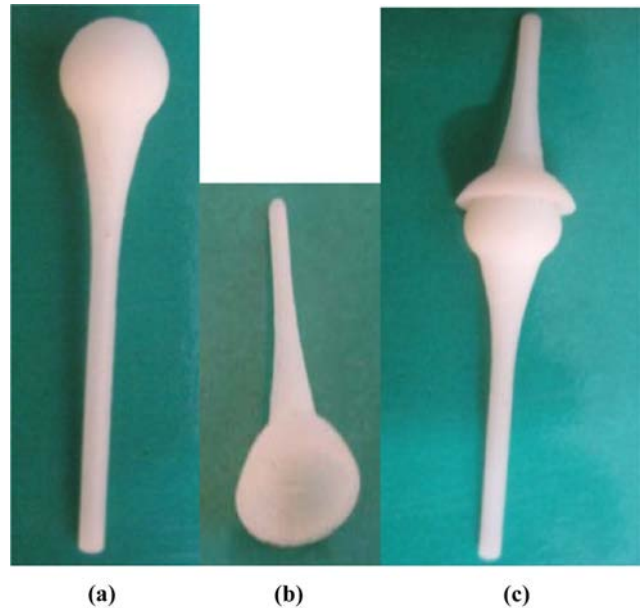During normal walking, there is a single-support phase when only one foot is in contact with the ground. During the

Figure 4 CAD model in Pro/E wildfire 4.0 (PTC)



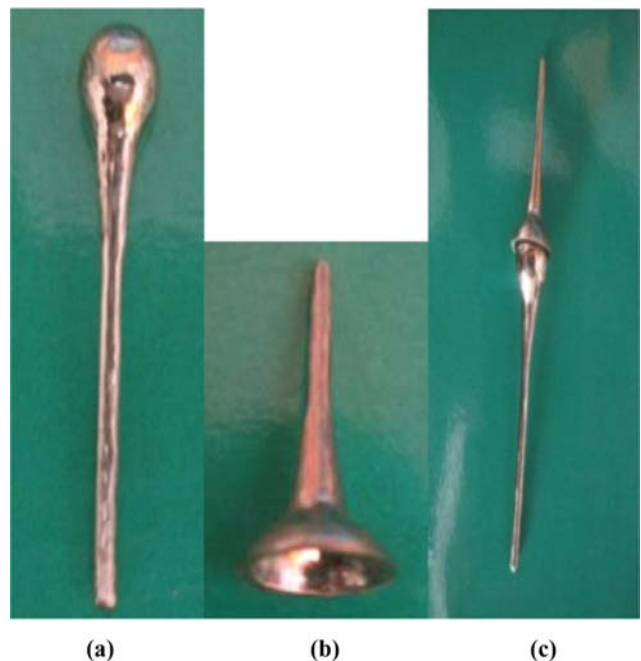Notes: (a) Metatarsal implant; (b) phalange implant

Figure 5



Notes: (a) ABS model of metatarsal implant developed using RP; (b) ABS model of phalange implant developed using RP; (c) positioning of ABS model of MTPJ implant (Samku)

Figure 6 Final MTPJ implant (SamKu) of cobalt chrome



Notes: (a) Metatarsal implant; (b) phalange implant; (c) positioning of MTPJ implant (SamKu) after implantation

“push off” phase, the heel leaves the ground, and the loading on the forefoot exceeds body weight by about 20 per cent. Around 40 per cent of body weight is imposed on the toes in the final stages of forefoot contact. Most of this is imposed on the great toe. Toe loads are counteracted by tension in the toe

flexor tendons and tendon sheaths. These forces react against the MTPJs to produce a joint force around 600 N in the first joint and around 100 N in the fifth. There was considerable variability in the distribution of load on the forefoot between individuals. In most of the normal feet studied, the forces in the rays of the forefoot were ranked in sequence so that the first ray carried the highest loads and the fifth carried the smallest loads (Stokes *et al.*, 1979). In a normal gait, the weight is transferred smoothly from the heel at contact through the forefoot at propulsion, and the load carried by the normal midfoot is low (Wrobel *et al.*, 2004; Stott *et al.*, 1973). Normally, the MTPJ delivers minimum forces while normal walking and maximum while running. The MTPJ implant (SamKu) was designed by considering load on the implant while running.

2.3 Analysis of design of implant using Finite Element Method

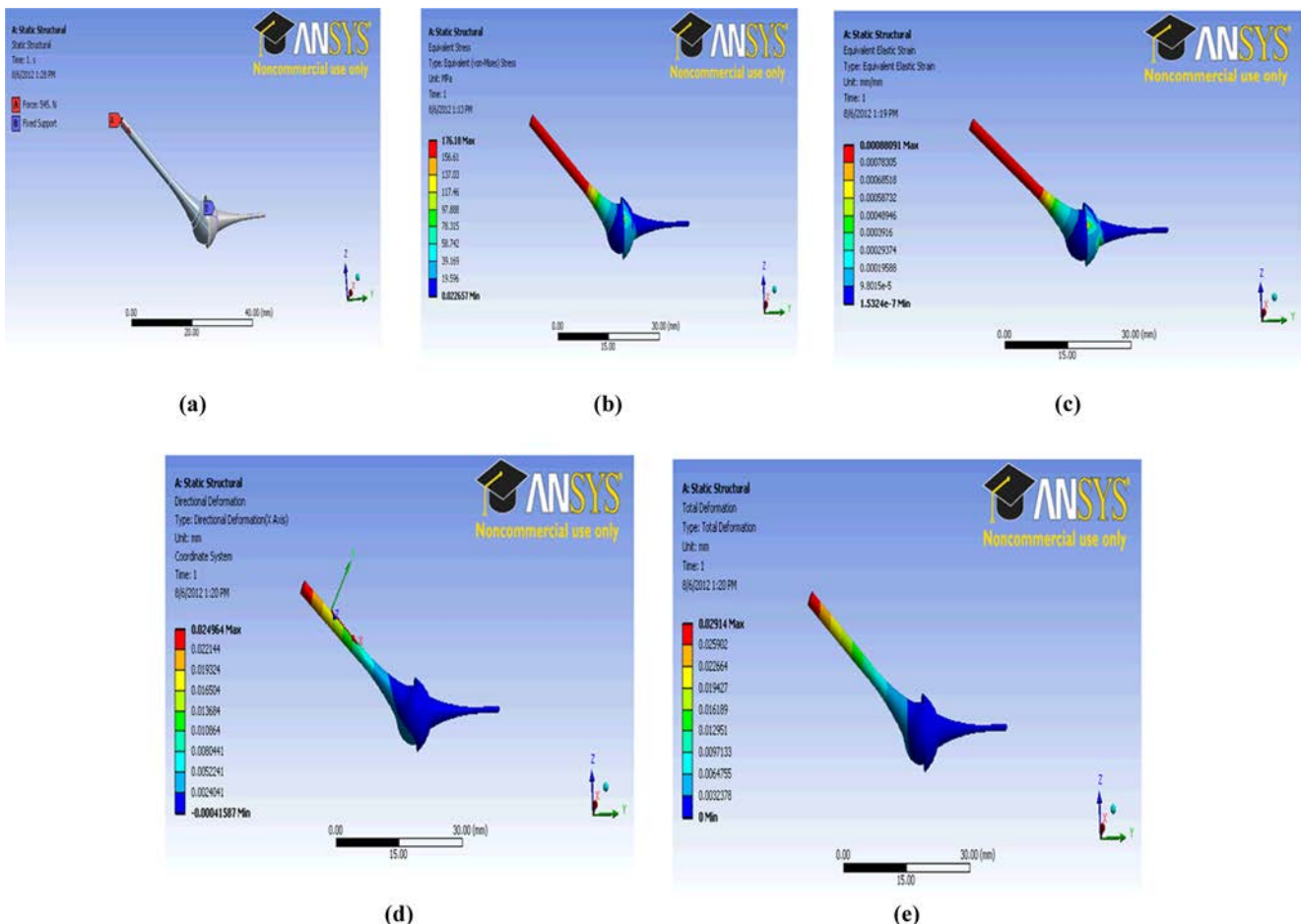
A linear analysis is carried out using ANSYS 14.0 Workbench. Metatarsal and phalanges CAD models are generated as per the dimensions from the available radiograph of the patient. The three-dimensional finite element models based on anthropometric measurements are developed having 3,197 nodes and 1,545

elements. The implant models were imported in Ansys as .igs format files to reduce data loss. The implant is an uncemented type, so suitable constraint was applied on the implant. Two implants are assembled in such a way that the metatarsal implant makes an angle of 46° (Giddings *et al.*, 1999) with the surface because a maximum load is applied on the MTPJ at this angle. The force of 545 N in the X-axis direction [Figure 7(a)] was applied on the central portion of the metatarsal tail axially (Stokes *et al.*, 1979).

The material SS316L is selected. The material properties, viz. Young’s modulus 2E5 MPa and Poisson’s ratio 0.3, are used for the assembly of the MTPJ. Boundary conditions selected are applicable to walking and running conditions. The weight of the person is 70 kg. The point of application of the force and the mesh parameters are carefully selected.

The maximum von Mises stress was 176.18 MPa [Figure 7(b)] and the maximum X-directional displacement was 0.024964 mm [Figure 7(d)]. The maximum equivalent elastic strain is 0.00088091 [Figure 7(c)] and maximum total deformation is 0.02914 [Figure 7(e)]. The allowable stress of the material SS316L is 558 MPa. So the customized implant (Samku) is within the safety limit.

Figure 7



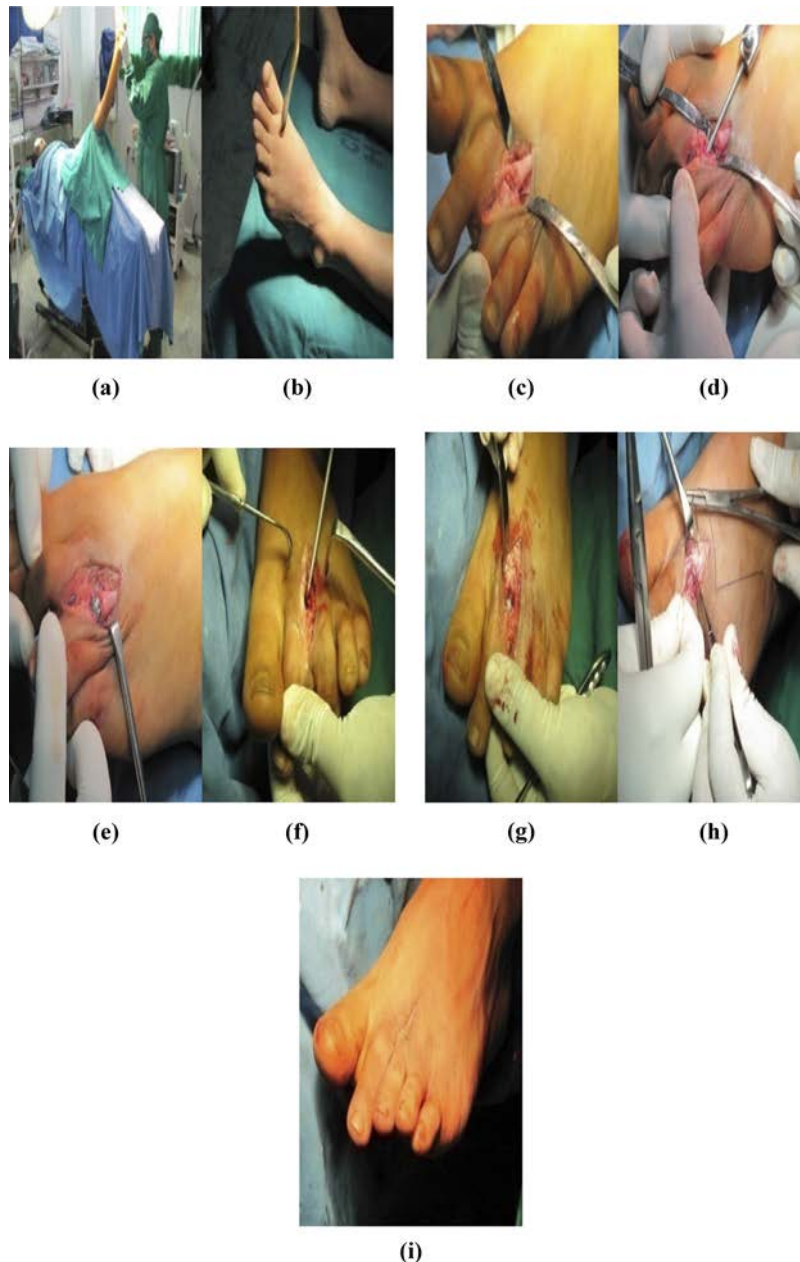
Notes: (a) Loading and boundary conditions; (b) equivalent von Mises stress; (c) equivalent elastic strain; (d) directional deformation (X-axis); (e) total deformation

2.4 Surgical outcomes

MTPJ replacement was carried out under regional (spinal) anesthesia using tourniquet control. First, location of incision was decided. An incision is made between the second and third MTPJs of the left foot, and the capsule is exposed by dividing tissue and retracting the tendon. Then, the articular surface of the third MTPJ was excised, and drilling was done in the third metatarsal and phalanges to the isthmus of the

bones with the help of a drill bit. A customized metallic phalangeal implant was first inserted through the pre-auricular incision in the third phalanges. Then, the customized metallic metatarsal implant was also inserted through the same incision in the third metatarsal, and the ball (head) and socket (cup) of the metatarsal and phalanges implant were adjusted in such a way that they assemble and work properly (Figure 8). The same procedure was carried out with the second phalanges

Figure 8



Notes: (a) Pre-operative preparation; (b) marking of site; (c) incision and dissection; (d) drilling with the help of drill bit in the third metatarsal and phalanges; (e) insertion of the MTPJ implant (SamKu) in the third metatarsal and phalanges; (f) drilling with the help of drill bit in the second metatarsal and phalanges; (g) insertion of the MTPJ implant (SamKu) in the second metatarsal and phalanges; (h) stitching; (i) the MTPJ implant (SamKu) after operation

and metatarsal joint with the customized metallic MTPJ implant (SamKu) in the same pre-auricular incision. The neck and stem of the implants had serrated surfaces for proper fixation and holding of the implants into the bones. All implant fixations were uncemented. An uncemented implant is useful to avoid problems with cement loosening (Wachtl *et al.*, 1996). The position/movement of the joints and a final status were confirmed on a C-arm/IITV (image intensifier television) machine. The total time required for the operation was 1 h. The patient was discharged on the fifth day from the surgery, and the stitches were removed after 15 days. The radiographs performed after the surgery showed the normal functioning joint without any loosening, migration or instability. The patient was allowed to walk normally, but

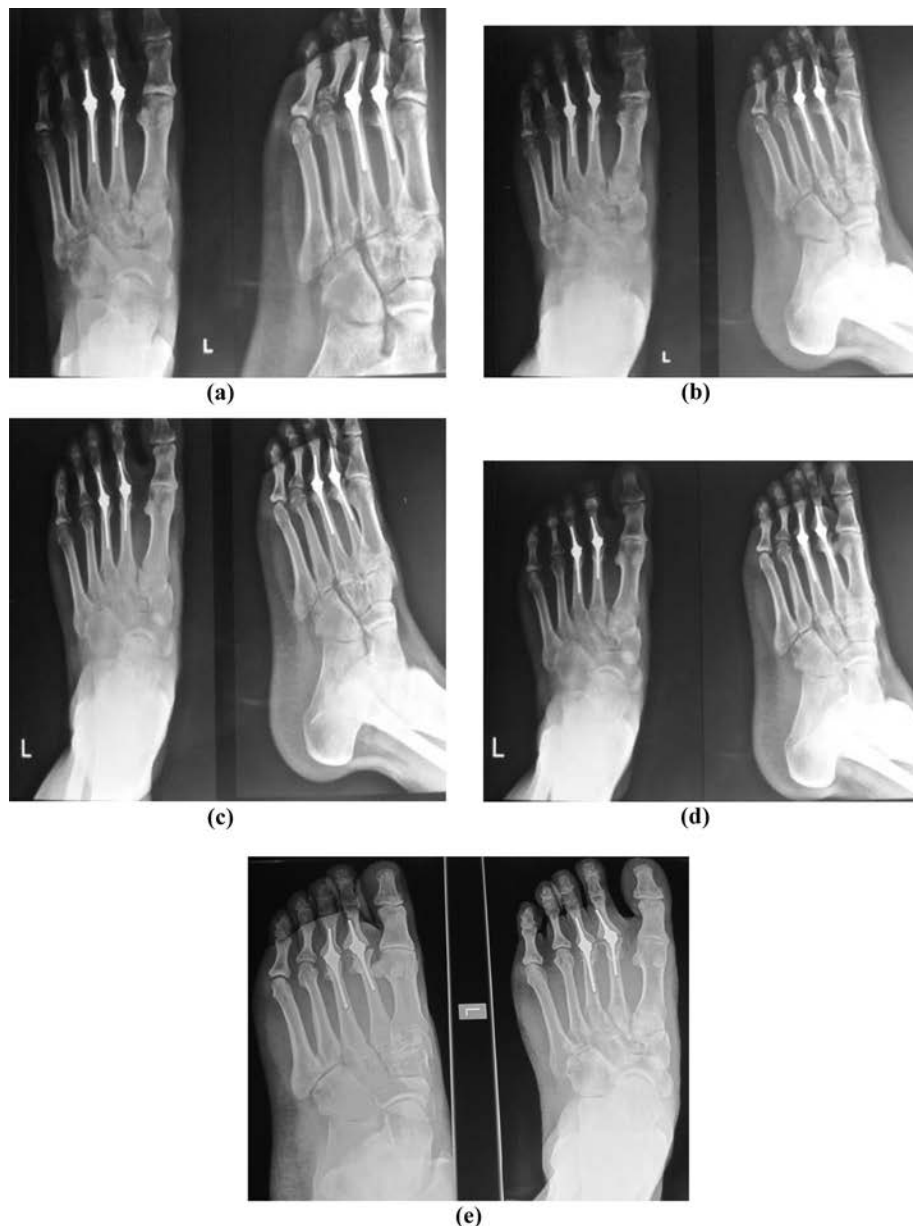
avoiding running, jerks, stress and strain. Patient was advised to wear protective shoes following surgery.

3. Results and discussions

This paper describes the novel method for developing the MTPJ metallic implant using RP and an advanced manufacturing technology. The results and the observations have revealed that the fabrication of the customized MTPJ implant (SamKu) with a high degree of accuracy is possible using RP.

The ball and the socket-type customized MTPJ prosthesis has two components: a metatarsals ball (head) and a phalanges socket (cup). The MTPJ implant fabricated considering the patient's specific needs possesses the following features:

Figure 9 Follow-up after



Notes: (a) 1 month; (b) 2 months; (c) 6 months; (d) 11 months; (e) 2 years

- It is simple and more concise than commercially available prostheses.
- Fixation area is less; hence surgery is performed through a single small incision.
- It is a universal implant, which can be used on any MTPJ with soft tissue stability.
- Surgical time is reduced owing to perfect fit and a single incision.

The implant as described has several advantages, but certain care and long-term studies are required to put it forward for widespread commercial application. The suggested approach allowed rectifying all possible errors in the implant shape and size prior to the surgery and eliminates the revision surgery in case of probable failures. The only demerit of the customized implant was the cost of the RP application in designing.

4. Follow-ups and X-rays of patient post-surgery and comments

The follow-ups are scheduled 1 month, 2 months, 6 months, 11 months and 2 years after surgery as shown in Figure 9.

The following points have been observed after follow-ups.

- slight deviation of implant from its original position, indicating changes in stress and strain pattern during locomotion of MTPJ;
- osteopenia; and
- temperature liability.

5. Conclusions

An RP technology has been shown to be a viable method for the pre-surgical planning and the development of the customized implant. Postoperatively, the MTPJ implant (SamKu) proved successful and presented no major difficulties. This is the first case; the patient is under regular follow-up evaluation. The post-operative results are overwhelmingly positive; however, the long-term results are awaited.

References

- Balazic, M. and Kopac, J. (2007), "Improvements of medical implants based on modern materials and new technologies", *Journal of Achievement in Materials and Manufacturing Engineering*, Vol. 25 No. 2, pp. 31-34.
- Bharath, V., Dharam, P.N. and Henderson, M. (2000), "Sensitivity of RP surface finish to process parameter variation", *Proceedings of the International Conference on Solid Free-form Fabrication, San Francisco, CA, 24-26 April*, pp. 251-258, available at: http://i3dea.asu.edu/data/docs-pubs/sensitivity-of_rp_surface_finish_to_processparameter_variation.pdf (accessed 1 December 2011).
- Chua, C.K., Chou, S.N., Lin, S.C., Lee, S.T. and Saw, C.A. (2000), "Facial prosthetic model fabrication using rapid prototyping tools", *Integrated manufacturing Systems*, Vol. 11 No. 1, pp. 42-53.
- Deshmukh, T.R., Kuthe, A.M., Chaware, S.M., Vaibhav, B. and Ingole, D.S. (2011), "Rapid prototyping assisted fabrication of the customized temporomandibular joint implant: a case report", *Rapid prototyping Journal*, Vol. 17 No. 5, pp. 362-368.
- Giddings, V.L., Beaupre, G.S., Whalen, R.T. and Carter, D.R. (1999), "Calcaneal loading during walking and running", *Official journal of American college of sports medicine*, Vol. 32 No. 3, pp. 627-634.
- Gopakumar, S. (2004), "RP in medicine: a case study in cranial reconstructive surgery", *Rapid Prototyping Journal*, Vol. 10 No. 3, pp. 207-211.
- Grondal, L., Brostrom, E., Wretenberg, P. and Stark, A. (2006), "Arthrodesis versus Mayo resection-The management of the first metatarsophalangeal joint in reconstruction of the rheumatoid forefoot", *The Journal of Bone and Surgery (Br)*, Vol. 88-B No. 7, pp. 914-919.
- Hatch, R.L. and Hacking, S. (2003), "Evaluation and management of toe fractures", *American Family Physician*, Vol. 68 No. 12, pp. 2413-2418, available at: Web site at www.aafp.org/afp (accessed 28 November 2011).
- Hibi, H., Sawaki, Y. and Ueda, M. (1997), "Three-dimensional model simulation in orthognathic surgery", *International Journal of Aduh Orthodontics attd Orthognathic Surgery*, Vol. 12 No. 3, pp. 226-232.
- Hieu, L.C., Bohez, E., Vander Sloten, J., Phien, H.N., Vatcharaporn, E., Binh, P.H., An, P.V. and Oris, P. (2003), "Case study: design for medical rapid prototyping of cranioplasty implants", *Rapid Prototyping Journal*, Vol. 9 No. 3, pp. 175-186.
- Hofstaetter, S.G., Hofstaetter, J.G., Petroustas, J.A., Gruber, F., Ritschl, P. and Trnka, H.-J. (2005), "The Weil osteotomy-a seven year follow-up", *The Journal of Bone and Surgery (Br)*, Vol. 87-B No. 11, pp. 1507-1511.
- Joshi, M.D., Dange, S.P. and Khalikar, A.N. (2006), "Rapid prototyping technology in maxillofacial prosthodontics", *The Journal of Indian Prosthodontic Society*, Vol. 6 No. 4, pp. 175-178.
- Ng, P., Lee, P.S.V. and Goh, J.C.H. (2002), "Prosthetic sockets fabrication using rapid prototyping technology", *Rapid Prototyping Journal*, Vol. 8 No. 1, pp. 53-59.
- O'Doherty, O.P., Lowrie, I.G., Magnussen, P.A. and Gregg, P.J. (1990), "The management of the painful first metatarsophalangeal joint in the older patient", *The Journal of Bone and Surgery (Br)*, Vol. 72-B No. 5, pp. 839-842.
- Pai, V., Mitchell, R. and Pai, V. (2008), "Irreducible dislocation of the metatarsophalangeal joints of the foot: a case report", *The foot and ankle journal*, Vol. 1 No. 5, pp. 129-134.
- Petzold, R., Zeilhofer, H.F. and Kalender, W.A. (1999), "Rapid prototyping technology in medicine-basics and applications", *Computerized Medical Imaging and Graphics*, Vol. 23 No. 5, pp. 277-284.
- Sekou, S., Lian, Q., Wang, W.P., Wang, J., Liu, Y., Li, D. and Lu, B. (2009), "Rapid prototyping assisted surgery planning and custom implant design", *Rapid Prototyping Journal*, Vol. 15 No. 1, pp. 19-23.
- Stokes, I.A.F., Hutton, W.C. and Stott, J.R.R. (1979), "Forces acting on the metatarsals during normal

- walking”, *Anat. Soc. G.B. and I.*, Vol. 129-A No. 3, pp. 589-590.
- Stott, J.R.R., Hutton, W.C. and Stokes, I.A.F. (1973), “Forces under the foot”, *The Journal of Bone and Surgery (Br)*, Vol. 55-B No. 2, pp. 335-344.
- Trieb, K. (2005), “Management of the foot in rheumatoid arthritis”, *The Journal of Bone and Surgery (Br)*, Vol. 87-B No. 9, pp. 1171-1177.
- Truscott, M., de Beer, D.J., Booyesen, G.J. and Bernard, L.J. (2004), “Bone development through CT/CAD/CAM/RP”, available at: www.afpr.asso.fr/data/info/publications/040915_s5_7_aepr.pdf (accessed 2 February 2012).
- Wachtl, S.W. and Sennwald, G.R. (1996), “Non-cemented replacement of the trapeziometacarpal joint”, *The Journal of Bone and Surgery (Br)*, Vol. 78-B No. 5, pp. 787-792.
- Watson, M.S. (1974), “A long-term follow up of forefoot arthroplasty”, *The Journal of Bone and Surgery (Br)*, Vol. 56-B No. 3, pp. 527-533.
- Winder, J. and Bibb, R. (2005), “Medical rapid prototyping technologies: state of the art and current limitations for application in oral and maxillofacial Surgery”, *Journal of Oral and Maxillofacial Surgery*, Vol. 63 No. 7, pp. 1006-1015.

- Wrobel, J.S., Connolly, J.E. and Beach, M.L. (2004), “Associations between static and functional measures of joint function in the foot and ankle”, *Journal of the American Podiatric Medical Association*, Vol. 94 No. 6, pp. 536-541.
- Xu, F., Loh, H.T. and Wong, Y.S. (1999), “Considerations and selection of optimal orientation for different rapid prototyping systems”, *Rapid Prototyping Journal*, Vol. 5 No. 2, pp. 54-60.
- Yan, Y., Neville, A. and Dolson, D. (2007), “Tribo-corrosion properties of cobalt-based medical implant alloys in simulated biological environments”, *Wear*, Vol. 263 Nos. 7/12, pp. 1417-1422.

Further reading

- Hryniernicz, T., Rokosz, K. and Filippi, M. (2009), “Biomaterial studies on AISI 316L stainless steel after magnetoelectropolishing”, *Materials*, Vol. 2 No. 1, pp. 129-145.

Corresponding author

Sameer C. Raghatate can be contacted at: amkme2002@yahoo.com